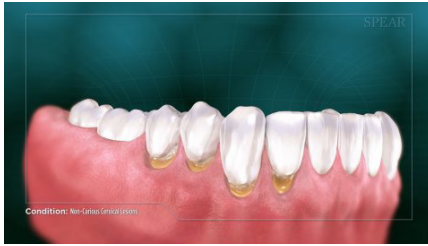
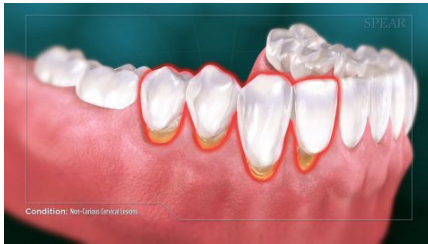
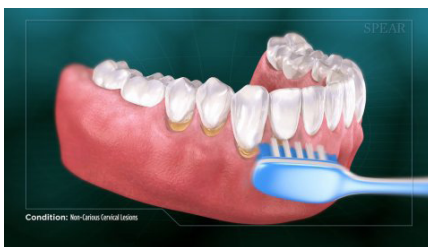Non-Carious Cervical Lesions



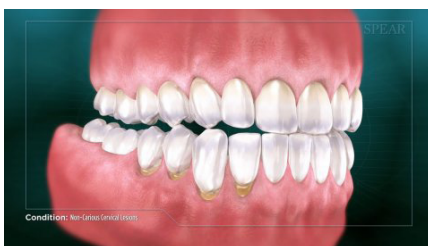
Non-carious Cervical Lesions describes a condition where tooth structure is lost below the gumline due to forces other than decay.



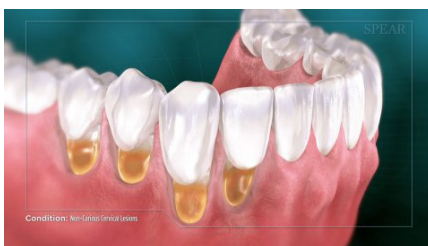Symptoms of Non-carious cervical lesions are often visual, with notches appearing on the teeth where the crown and root of the tooth meet. They can sometimes be accompanied by gum recession in the area as well. Depending on the depth of the lesions, sensitivity and/or pain may also be present.



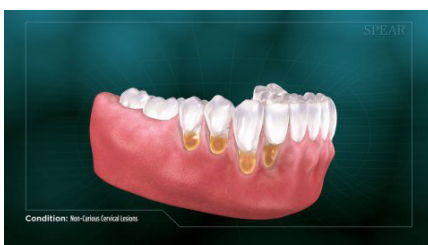Current research indicates two primary causes of these lesions- the first is abrasion, where the tooth material is reduced due to overly aggressive or improper tooth brushing technique.



The other possible cause is abfraction- which creates the notches by placing stress on the teeth through grinding and clenching. Your doctor will be able to determine the likely cause after a comprehensive examination.



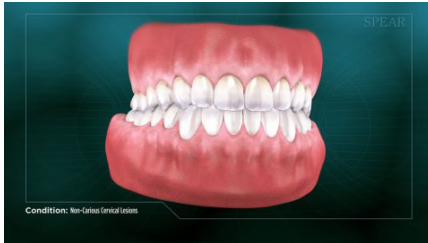
Given that tooth structure is much softer below the gumline, once these lesions begin to form they very quickly penetrate the outer layer of tooth structure and expose the softer dentin layer beneath. Once the dentin is exposed the pace of the wear will accelerate dramatically.



If allowed to progress, non carious cervical lesions can deepen and further expose the teeth to damage, making them weaker, more sensitive, and potentially prone to decay and fracture.



Non-Carious Cervical Lesions



There are preventative and corrective treatment options for patients showing evidence of non-carious cervical lesions. Treatment will vary based on the underlying cause and the extent of tooth damage, making it critical to work closely with your doctor to proactively address the issue before more damage occurs.

